Axial Spondyloarthritis

History: inflammatory back pain

- ↳ AM Stiffness >30 min
- ↳ improves w/ activity NOT w/ rest
- ↳ awakening in 2nd half of the night

Exam: lumbar lateral flexion

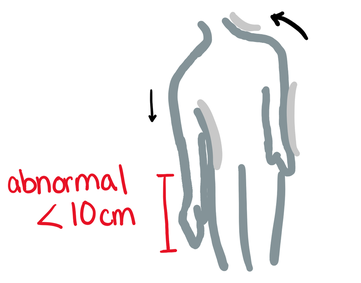

Peripheral Spondyloarthritis

History: inflammatory arthritis

- ↳ Stiffness, swelling, pain that improves w/ activity

Exam:

1. palpable swelling + warmth
2. distribution

oligoarticular

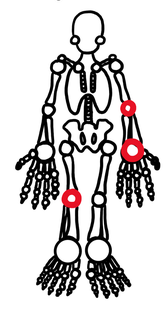

- asymmetric
- large joint

polyarticular

- DIP + PIP involved

SHARED FEATURES

MSK Findings

- Dactylitis
- Enthesitis

non-MSK Findings

← more axSpa associated — more peripheral spa associated →

- uveitis
- psoriasis 
- IBD

Lab Testing

- HLA-B27
- CRP / ESR

Imaging

Axial SpA

1st Line! X-Ray Pelvis AP

- evidence of sacroiliits?
- consistent structural damage? (SI erosions, fusion?)

yes → dx axSpA

no → non-contrast MRI pelvis (T2 STIR sequence enhancement)

Peripheral SpA

- bilateral plain films of affected joints

→ advance imaging only if exam/plain films not convincing of inflammation